

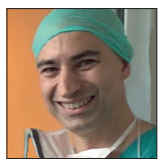
UroFusion

Transperineal and Transrectal Prostate Targeted Biopsies

Courtesy of
Dr. Andrea Zitella and Dr. Pietro Galluzzi



“UroFusion is a safe, quick and easy system to accurately perform good quality prostate target biopsy. Addition tools like 3D prostate volume rendering make possible to have a real time evaluation of prostate deformation and movements.”



Dr. Andrea Zitella
Head of oncology clinics S.C. Urology Hospital Molinette Hospital in Turin, Italy

Introduction

Ultrasound (US) examination represents the best solution for the doctors to guide the execution of prostate biopsy. It is the only real-time imaging technology that ensures an appropriate compromise in terms of image quality, tissue information, execution time and cost for the hospital.

According to the US nature, the echoes used to create the images could give additional information about tissue characteristics such as their mechanical specificities, which are particularly useful to characterize tissue lesions.

Today, the extended connectivity, the multimodality approach and the latest innovations introduced by the applications of Artificial Intelligence (AI) are opening new horizons in radiology imaging where US devices may play a central role in Cross-Modality Imaging.

Background

Prostate cancer is the most common neoplasm in male patients and is the second/third most common cause of death by cancer in the United States and Europe^[1,2,3,4]. The most common prostate diseases include prostatitis, benign prostatic hyperplasia and prostate cancer, the similar symptoms of which demonstrate the importance of periodic screening in men^[5].

Generally, if no symptoms of prostate disease occur, the routine screening consists of blood PSA examination and Digital Rectal Examination (DRE). If one of these two exams shows an abnormal response, the doctor can suggest a multiparametric MRI (mpMRI) examination; thanks to the merging of anatomical and functional information taken from T2-Weighted (T2W) imaging, Diffusion Weighted Imaging

(DWI), and Dynamic Contrast Enhanced (DCE) imaging, this currently represents the best solution in terms of accuracy for prostate imaging. After the results of the mpMRI examination, the doctor decides whether to proceed with a prostate biopsy to assess the nature of the suspected lesion or suggests active surveillance (AS) of the patient to avoid repeating biopsies^[6,7].

Prostate biopsy is the gold standard in the detection of prostate cancer (PCa)^[6]. The usual biopsy methodology is US-guided, but due to its high irregularity and the organization of the internal capsules, it is often impossible to distinguish the different characteristics of the prostate tissues. US-guided biopsy can therefore only suffer from a low grade of accuracy.

Evolution in the technique has led to the definition of systematic sampling of the prostate with a different number of samples in different areas, in accordance with the risk of developing neoplasms. A maximum of 12-15 samples are taken: 6 generally in the peripheral area, 4 in the transition zone and 2 from the apex. In term of PCa detection rate, systematic biopsy (SB) represents the best solution with a rate of almost 70% of cancer detection^[6].

Even so, the statistical relevance of missing significant tumors is pushing research to find other ways to increase its precision.

The evolution of mpMRI image quality and the extended US connectivity and multimodality approach known as fusion imaging have opened the avenue to combine mpMRI images with real-time US results. This method makes it possible to fix a target on a suspected lesion found on MRI images and, after synchronization with the US modality, to visualize the target on the US in the same location^[7]. The combination of mpMRI images and US enables doctors to progress from conventional SB to targeted biopsies (TB)^[8,9]. The increase in the detection rate due to the combination of TB and SB have resulted in its strong recommendation in the recent Guidelines^[10].

MRI/US fusion imaging can be cognitive or software-based:

1. Cognitive: if the doctor uses the MRI report and images to assess the location of the lesion and tries to reach it by sampling the same portion during the US-guided biopsy.
2. Software: if the US system combines automatically the two US and MRI datasets, to provide information about the target localization and increase the sampling accuracy.

Prostate Biopsy in Transperineal (TP) and Transrectal (TR) configuration

The TR biopsy approach currently represents the most common methodology for prostate biopsy^[11]. The procedure is considered low risk for the patient, with 50% suffering from minor complications such as hematuria or hematospermia, to severe complications. However, there is a possibility of 4-5% of cases requiring hospital admission due to infection or related complications. As well as representing risk to the patient, these complications can represent a burden on the National Health Service in terms of increased costs. Other approaches must therefore be considered^[11].

“The biplane co-registration system guarantees a more precise fusion and superimposition of US and mp-MRI, an indispensable prerequisite for correct centering of the lesions, even those not identifiable with US.”



Dr. Pietro Galluzzi
 Director of the Diagnostic and Interventional Ultrasound Operating Unit of Valduce Hospital in Como, Italy

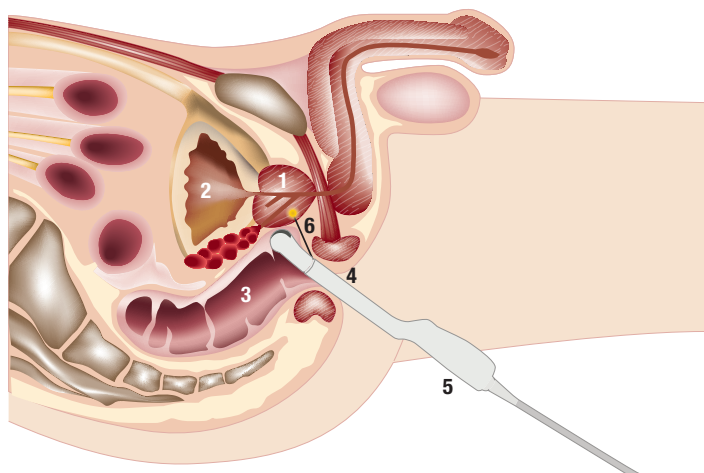


Fig. 1 TR biopsy

- | | |
|------------|--------------------|
| 1 Prostate | 4 Anus |
| 2 Bladder | 5 Ultrasound probe |
| 3 Rectum | 6 Needle |

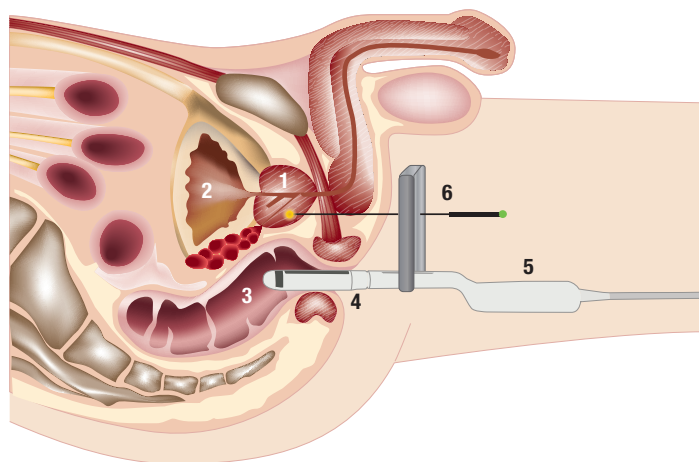


Fig. 3 TP biopsy

- | | |
|------------|---|
| 1 Prostate | 4 Anus |
| 2 Bladder | 5 Ultrasound probe |
| 3 Rectum | 6 Biopsy grid in front of skin behind scrotum |

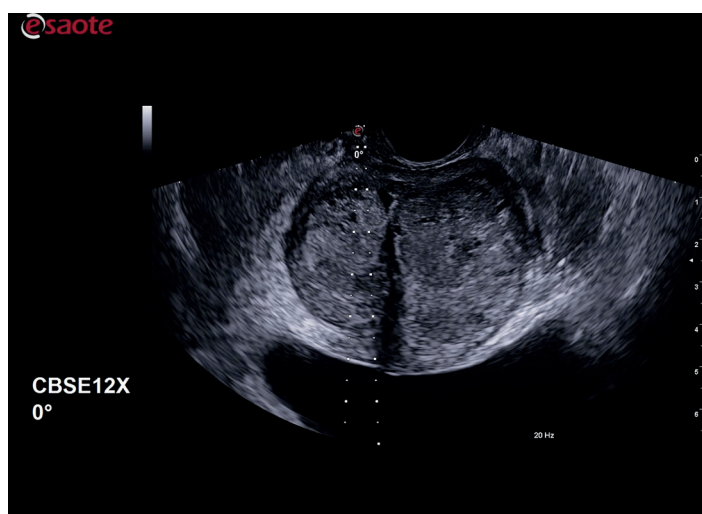


Figure 2 US image of the prostate with the E 3-12 probe, via the TR approach.

The TP approach is a safer alternative biopsy technique. This method reduces the risk of post-operative infections and greatly improves cancer detection rates in the anterior and apical areas of the prostate. In addition, based on its low risk, this technique is strongly suggested by the latest Guidelines^[10]. Even so, it remains less commonly used, due to its technical difficulty and pain for the patient^[12].

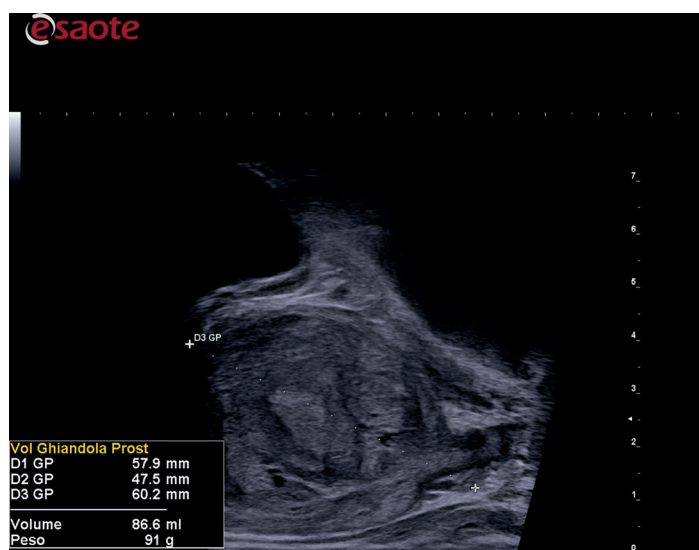

Figure 4 US prostate image with the TLC 3-13 probe, via the TP approach.

Equipment

UroFusion is available as part of the MyLab™X90, MyLab™X9, MyLab™9 family and MyLab™X8 eXP, and is compatible with two dedicated probes: the end-fire probe E 3-12 for a transrectal (TR) approach and the biplanar linear-convex array probe TLC 3-13 for a transperineal (TP) approach.




Fig. 5 Esaote S.p.A. endo-cavitary probes enable the UroFusion navigation tool, given the option for the doctor to execute the intervention in two configurations: TR with a E 3-12 probe and TP with a TLC 3-13 probe.

The hardware is based on an electromagnetic tracking system, consisting of a magnetic field generator and a receiver antenna positioned on the endo-cavitary probe. The antenna makes it possible to detect the position of the transducer in a three-dimensional field created by the electromagnetic transmitter. The UroFusion software enables simultaneous registration of the datasets of a second DICOM (Digital Imaging and Communication in Medicine) modality and real-time ultrasound. The width of the magnetic field is approximately 70 cm from the magnet.

The quality of the tracking is continuously monitored and is reported on the screen as blue lines in the signal field.

When UroFusion is active, a dedicated environment is displayed on the touchscreen to facilitate the workflow and acquisitions.

Findings and procedures (TP approach)

In this case, the needle access is through the perineum. Today, this approach represents the safest solution for the patient in term of post operative infections, with no risk of multiple occurrences of sepsis. The procedure is split into four steps:

1. Preparation stage:

The operator will import into the US device one or more DICOM datasets, such as MRI, CT, or PET-CT, directly from a PACS or from external media, e.g. a CD or USB stick. Generally, for prostate biopsies, T2-weighted axial and sagittal MRI sequences are imported to be used for navigation. Additionally, the clinician can import other datasets, such as Diffusion Weighted Imaging (DWI) series and Apparent Diffusion Coefficient (ADC) series. UroFusion then makes it possible to combine these with the T2 datasets to help find the precise location of the targets.

The alignment between the different series can be managed automatically via the “Auto Series Alignment” function or manually by the clinician.

Up to 25 targets can be set by the operator, either with a 3D ball using the “Focal lesion” button on the touchscreen, with manual 3D contouring, or finally with automatic 3D contouring of the lesion if well differentiated in the MRI dataset.

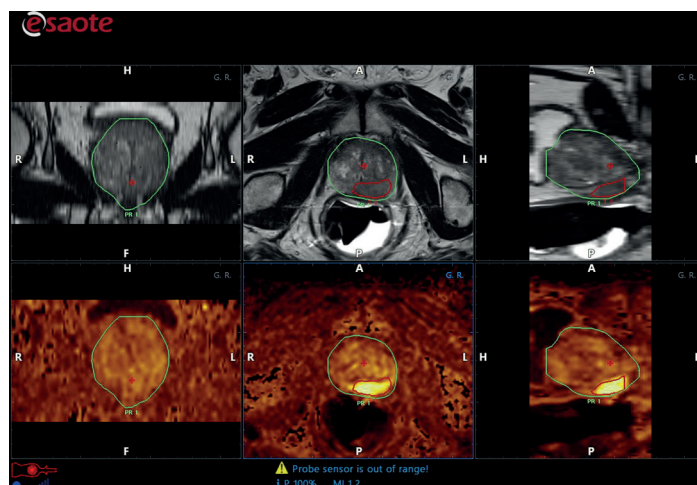


Fig. 6 Example of updates to and superimposition of mp-MRI images in a UroFusion environment. In this case, the primary image is represented by the axial axis of the weighted T2; the secondary by the DWI.

This tool provides the option to obtain a rapid 3D reconstruction of the prostate volume using to an AI algorithm, which automatically plots the prostate contours for subsequent use in automatic alignment. The prostate is a soft organ which suffers important deformations due to the endo-cavitary probe and the mp-MRI coil. Also for this reason the mp-MRI volume allows to understand in real-time the compression grade made by the probe and to adequate it to the fusion methodic.

2. Automatic Alignment stage:

During this step, the operator synchronizes the ultrasound findings in real time with the MRI dataset. At this stage, the first plane is selected (in the case shown, the doctor used a sagittal view, but it is also possible to start from the axial plane), then the alignment is made in 3D, by swiping over the entire gland area.

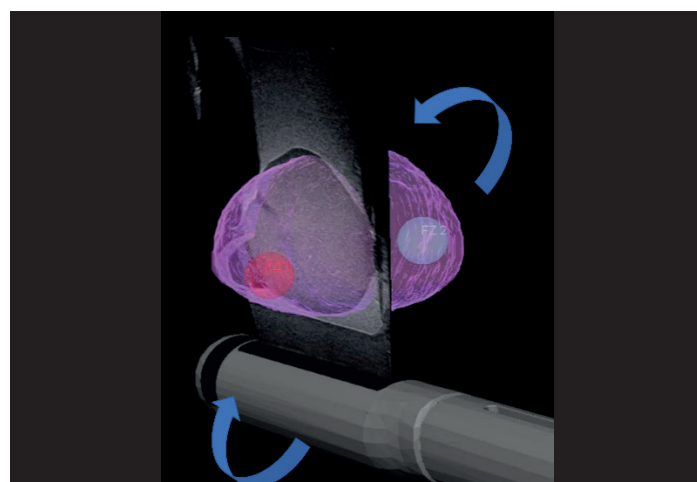


Fig. 7 US beam projection during a 3D sagittal swipe with the TLC 3-13 probe.

After 3D recording, the system can automatically plot the contours of the prostate volume using US, and simultaneously calculates the MRI findings to synchronize the two modalities. Once the sync is complete, UroFusion will pass directly to the Navigation stage.

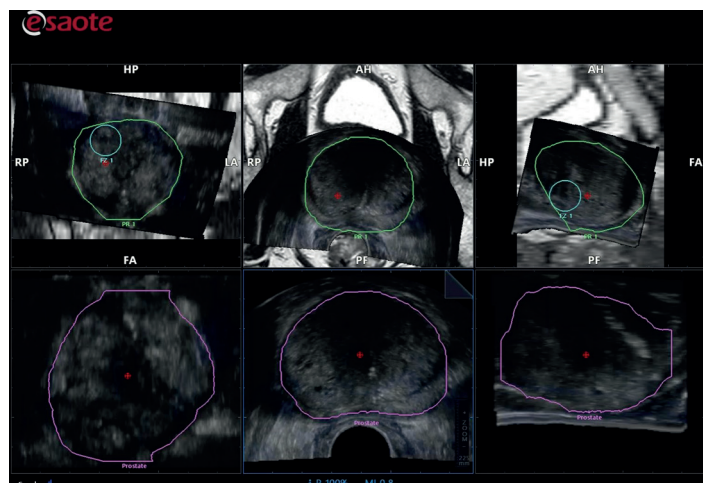


Fig. 8 Superimposition of the 3D US volume with the MRI findings, during automatic synchronization.

3. Fine-tuning stage:

The practitioner can easily adjust or redo the alignment when it is made via different fast tuning systems.

- A 3D US volume registration of the prostate, where the alignment of the current findings is adjusted to minimize the distance between the two volumes.
- Via the One-Point Registration which enables the repetition of the two modalities, placing a point in the same position in both of them.
- Freehand Tuning makes it possible to move and rotate the MRI image manually and/or change the MRI image plane, to achieve an alignment of the two modalities without repeating the co-registration phase.
- Internal Marker Tuning allows the operator to align the different planes of the images by marking the anatomical reference points that are clearly visible in both modalities. The system expects at least three points in the US and MRI dataset to align them.

4. Navigation and biopsy procedure stage:

The system is ready to navigate through the two modalities and the biopsies can be performed under US/MRI image fusion guidance. If more than one second modality dataset has been uploaded, the operator can change between them at any time, setting it as the benchmark. Different display layouts are available.

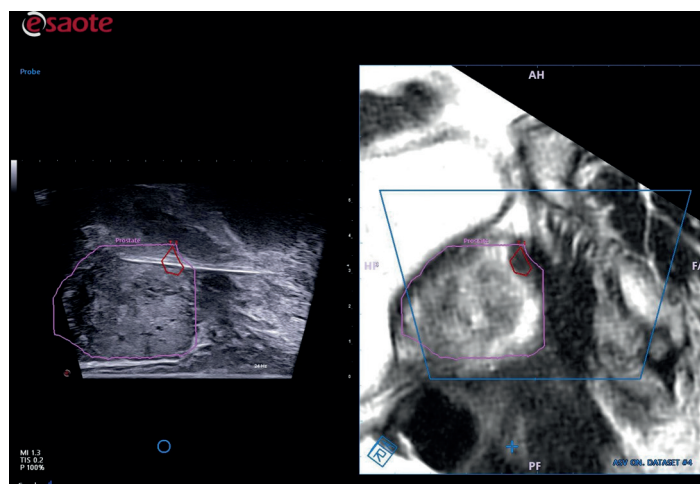


Fig. 9 Live US with the 2nd modality image on the same plane. Image Fusion with B-Mode and MRI dataset. This layout directly shows the two modalities side by side during the biopsy. The contour of the prostate volume makes it possible to observe prostate movements in real time, giving the doctor instruments to rapidly re-synchronize the two modalities.

The physician can display the biopsy line from both the modalities on the monitor. Also in this stage, it is possible for the doctor to re-align the two modalities if patient movements or contractions occur. Both modalities can be frozen and the alignment rapidly repeated, as in the *Freehand Tuning* stage or *3D Registration* stage.

Another integrated tool is the Sample Mapping, used to report the position of each sample taken during the procedure with the option of saving the 3D volume with the mapping, or to review them later.

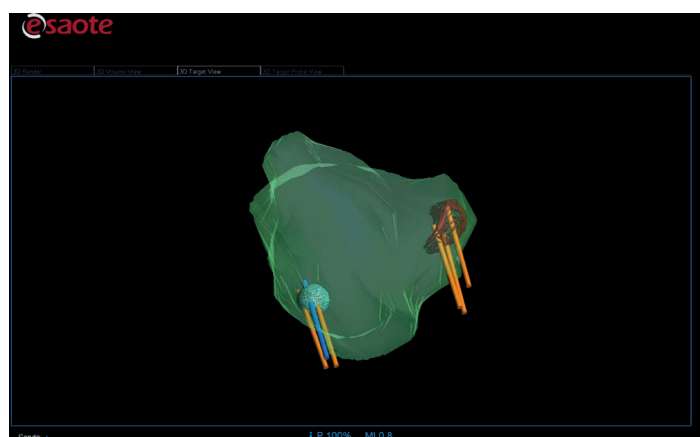


Fig. 10 3D rendering of the prostate gland with core samples mapping.

Findings and procedures (TR approach)

This approach is currently the most used method of prostate biopsy. Needle access is gained through the rectum and the system automatically sets the needle guide depending on the configuration and leaves the operator the option to set the correct needle configuration on a dedicated menu. To perform the biopsy the doctor can choose to take the samples from both the axial and sagittal planes.

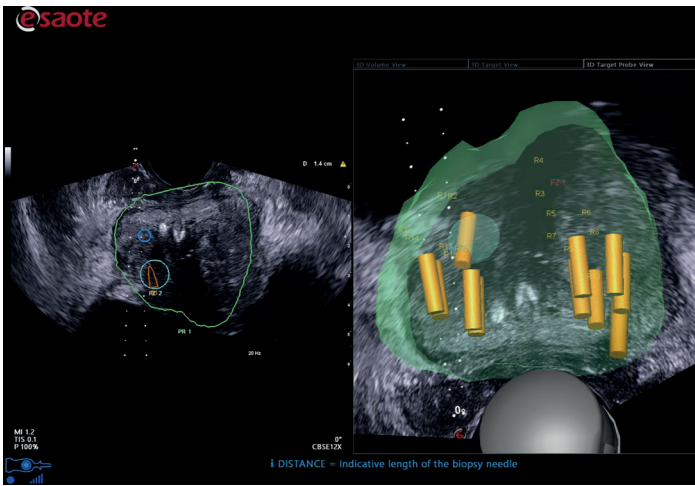


Fig. 11 TR biopsy with the needle guide and sample mapping activated. In the MRI volume, the doctor can observe in 3D how the samples are distributed across the gland.

The workflow is the same as in the TP approach; the main difference is that the 3D US volume registration must be performed from the apex to the base or vice versa in axial view.

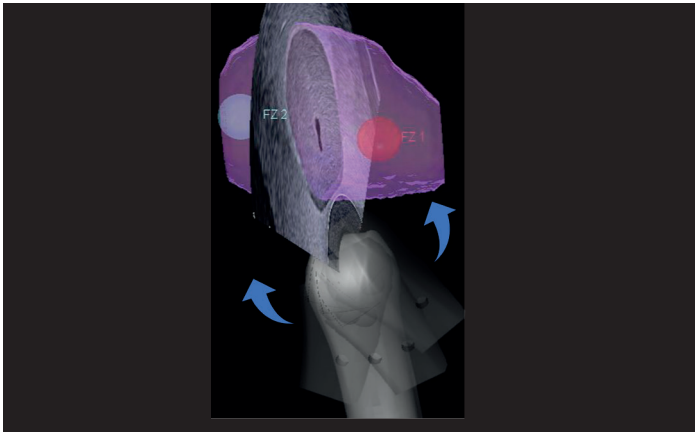


Fig. 12 US beam projection during a 3D axial swipe with the E 3-12 probe.

Additional features

In case of necessity, it is possible to synchronize the two modalities also manually: during this step, the operator synchronizes ultrasound by overlapping it in real time with the MRI dataset. The alignment is done by finding certain common markers in the two modalities, e.g. the urethral channel in the equatorial axis, or clearly visible cysts or bones. The prostate volume can assist in this stage, given that the overlap in the US image of the outline plotted on the MRI image can add other reference points for the operator. The physician can also change plan orientation of the two modalities to check the synchronization.

It is then possible to confirm the alignment made by clicking “Confirm the alignment” and going directly to the Navigation stage. The focus of this alignment approach is to better overlap and to fuse the two modalities, indispensable prerequisite for a correct centering of the lesions, even those not identifiable with US.

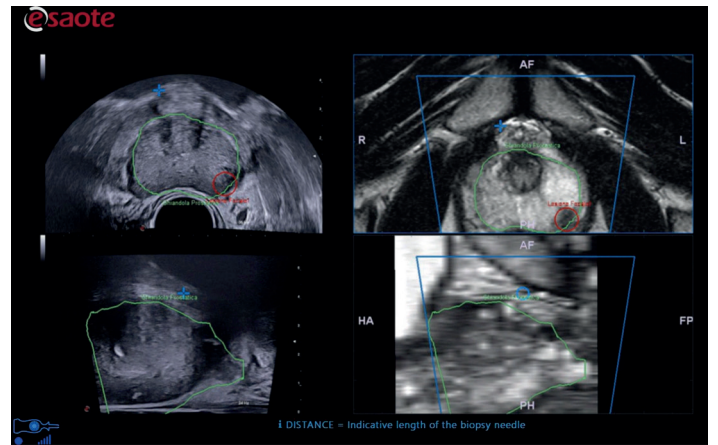


Fig. 13 Bi-planar alignment of the two modalities respect the sagittal axis with the bi-planar probe. In the latter case, the operator uses both the visualization to check the quality of the alignment.

Once the synchronization is complete, the patient must remain still to maintain a good quality of fusion. But sometimes, despite local anesthesia, the patient can experience involuntary movements or contractions. In these cases, to automatically correct these movements, a movement sensor can be applied to the patient's body. The application area could be the sacral zone if the patient stays in lateral decubitus position or the iliac crest if the patient is in gynecological position, to minimize the effects of movement artifacts.

The system also supports the Classic CIVCO Stepper* and the GfM Stepper*. Once calibration is complete, it can be used for targeted prostate biopsies for focal treatments, exploiting the precision and stability it offers.

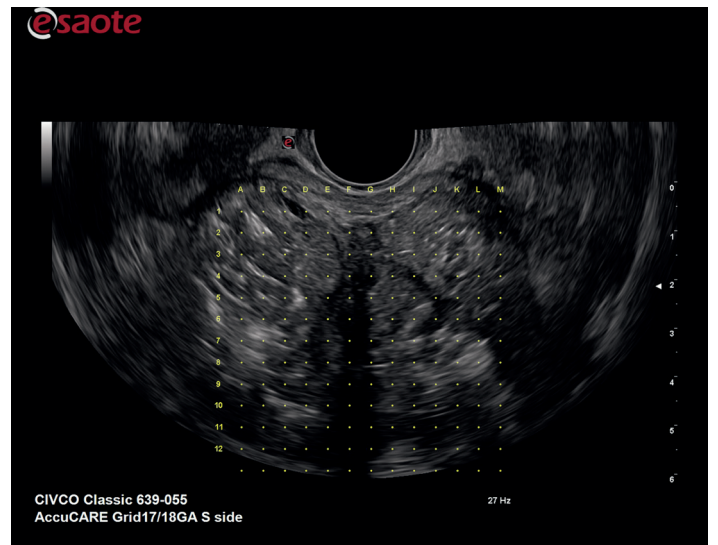


Fig. 14 Example of CIVCO Classic grid superimposed to live US image.

UroFusion environment can support additional technologies such as microV, the Esaote tool for microvascularization visualization; QElaxTo 2D, is the Esaote 2D shear wave technique for the stiffness evaluation of the prostate tissue; and CnTI™, the Esaote software for Contrast Enhancement Ultrasound (CEUS). All these techniques, available in real time during a fusion procedure, may improve the intervention capability and accuracy of the doctor, and enhance the quantity and quality of the information available.

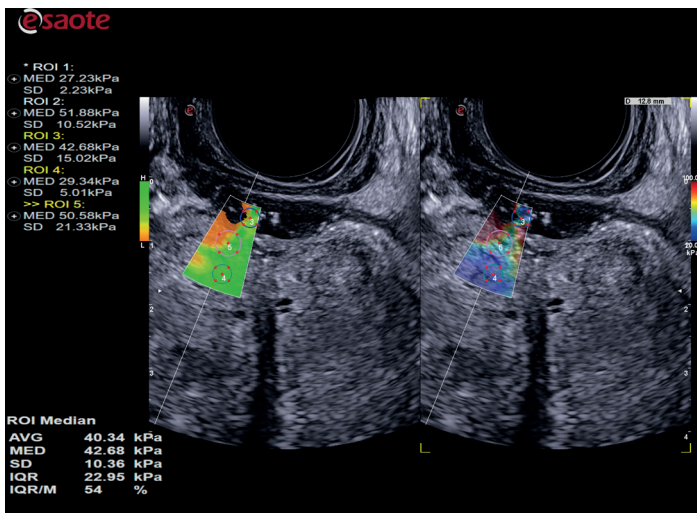


Fig. 15 QElaxTo 2D applied to prostate with dual mode visualization to enable the dispersion map (left side). The orange areas indicate low reliability while the green ones indicate high reliability, and the stiffness map imaging (right side).

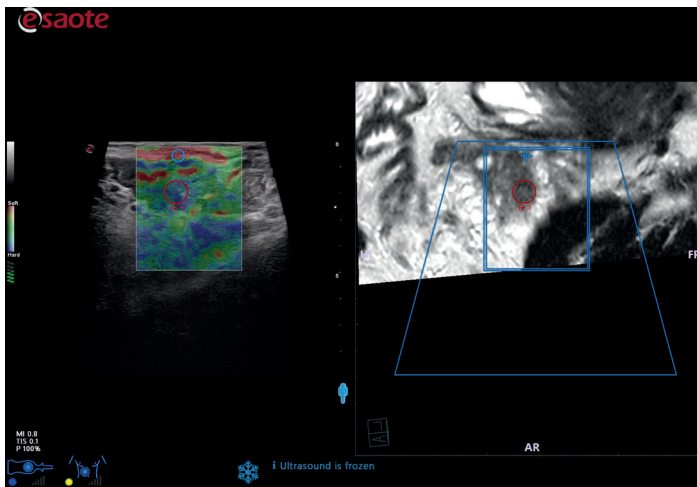


Fig. 16 Example of ElaXto application with the Bi-planar probe. The elasticity study of the tissue in UroFusion environment gives the doctor additional tools to study a lesion, suspected or otherwise.

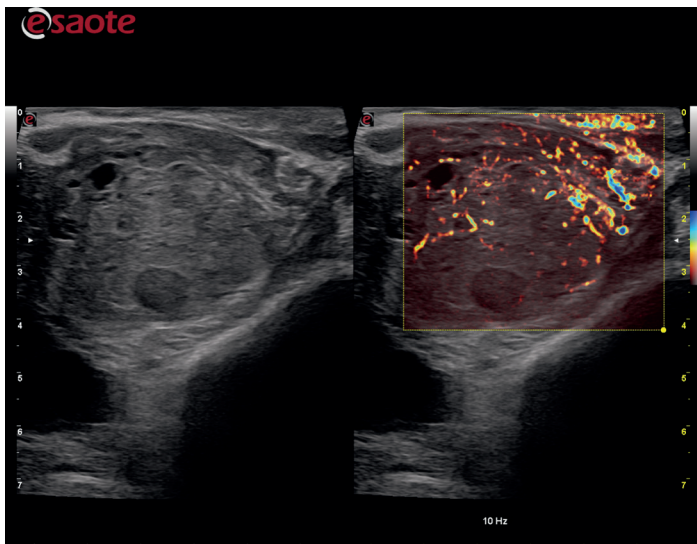


Fig. 17 Study of prostate gland microvascularization using microV expansion.

Conclusions

UroFusion is a completely dedicated prostate TB software package powered by Artificial Intelligence that supports medics in the precision sampling of a suspected lesion, combining the information from both MRI and US images.

The user is able to monitor any patient movement or organ deformation in real time and immediately, with fine-tuning tools or probe movement adjustment, can easily retrieve the alignment of the two modalities.

Additional tools such as the sample mapping are useful for the follow-up if further biopsies are required, and to plan any focal therapy procedure.

The possibility of having an automatic 3D reconstruction of the prostate volume and of the sampling already carried out allows the operator to evaluate both the number of correctly performed samples on the target and to adequately sampled some prostate volumes in the subsequent systematic mapping, especially in bulky prostates.

Target biopsy should become an everyday procedure, according to the guidelines, and UroFusion helps to execute this complex procedure with a smart workflow and with dedicated tools, from preparation to follow-up.

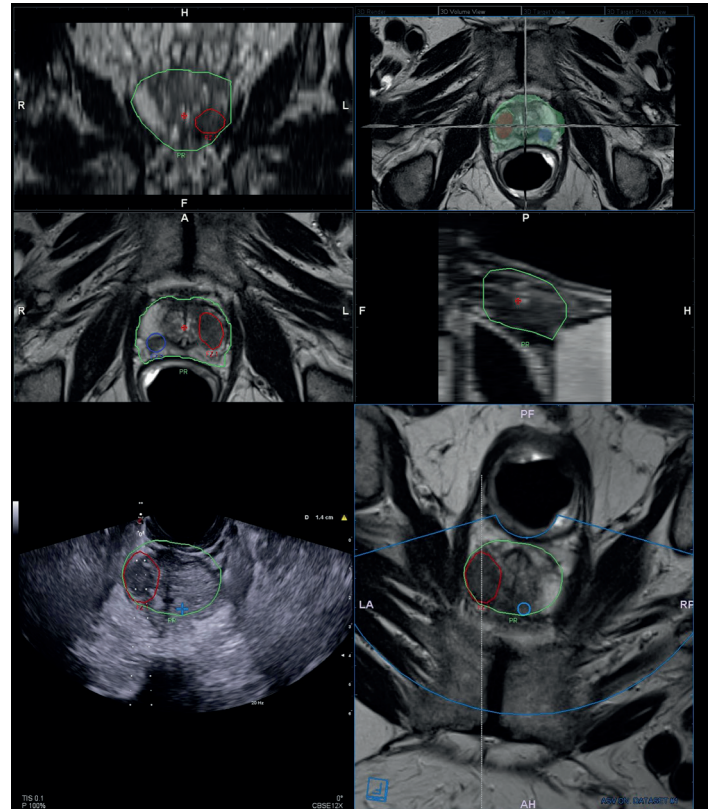


Fig. 18 In this case the MRI examination of the patient reports a PIRADS 5 lesion on the equatorial zone on the left side of the gland and a PIRADS 4 lesion in the contralateral position. Thanks to the possibility of multiple targeting geometries, the doctor can plot the contours of the lesions more efficiently. The contours of the prostate can be used as a benchmark to monitor prostate movements and as support for the alignment. The doctor takes 2-3 samples from the targeted region using the biopsy guide as support to reach it more precisely.

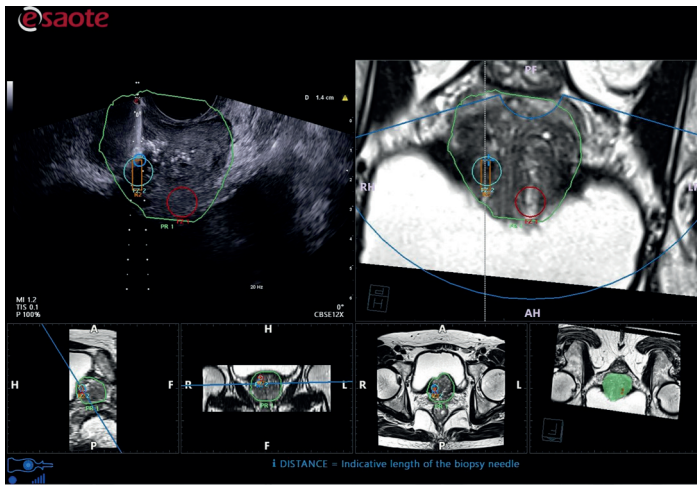


Fig. 19 Prostate mapping in real time in TR approach.

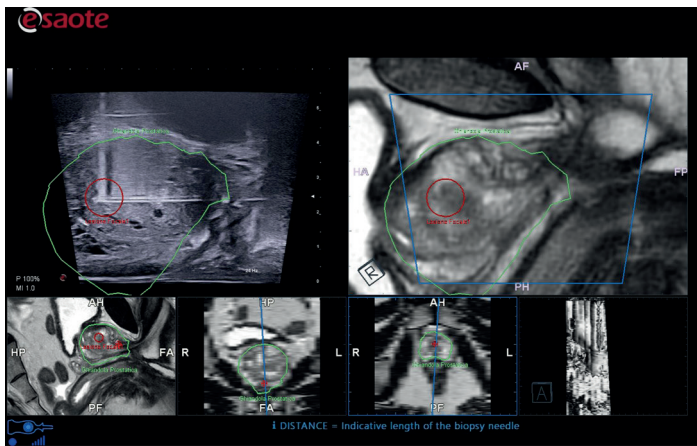


Fig. 20 Live US with the 2nd modality image on the same plane and all the second modality planes. This layout can provide information on the spatial position of the projection axes of the probe according to the synchronization achieved during the automatic registration. In this image, it is possible to notice the contribution of Fusion Imaging to detect a clear hypointense lesion on the T2W image but not visible on US.

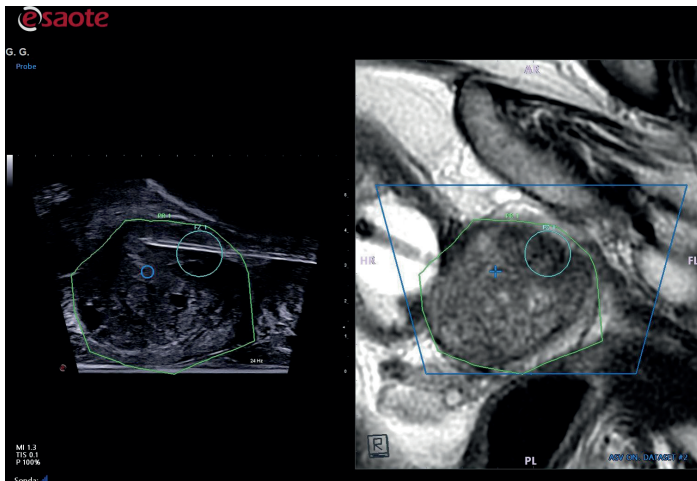


Fig. 21 Example of TP biopsy - After the samples are taken from the target area, the doctor progresses to a systematic biopsy of the gland (around 12 samples) to cover any lesions not visible on the MRI.

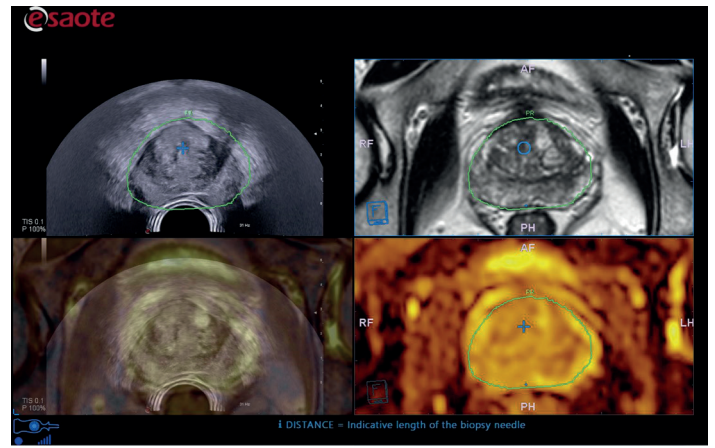


Fig. 22 Example of multimodality overlap of different datasets to search the lesion with a better precision.

References

- [1] Siegel R, Naishadham D, Jemal A. *Cancer statistics*, 2013. *CA Cancer J Clin* 2013;63(1):11-30
- [2] Z. Khan, N. Yahya, K. Alsaih, M.I. Al-Hiyali and F. Meriaudeau, *Recent Automatic Segmentation Algorithms of MRI Prostate Regions: A Review*, in *IEEE Access*, vol. 9, pp. 97878-97905, 2021, doi: 10.1109/ACCESS.2021.3090825.
- [3] Atlanta: American Cancer Society, 2017, [online] Available: <https://www.cancer.org/research/cancer-facts-statistics/all-cancer-facts-figures.html>.
- [4] Lionne D.F. Venderbos, André Deschamps, John Dowling, Ernst-Günter Carl, Sebastiaan Remmers, Hein van Poppel, Monique J. Roobol, *Europa Uomo Patient Reported Outcome Study (EUPROMS): Descriptive Statistics of a Prostate Cancer Survey from Patients for Patients*, *European Urology Focus*, Volume 7, Issue 5, 2021, Pages 987-994, ISSN 2405-4569, <https://doi.org/10.1016/j.euf.2020.11.002>.
- [5] Xia, Shu-Jie et al. An overview of prostate diseases and their characteristics specific to Asian men. *Asian journal of andrology* vol. 14,3 (2012): 458-64. doi:10.1038/aja.2010.137
- [6] P. Rajwa, B. Pradere, F. Quhal, K. Mori, E. Laukhina, N.A. Huebner, D. D'Andrea, A. Krzywon, S.R. Shim, Pascal A. Baltzer, R. Renard-Penna, M.S. Leapman, S.F. Shariat, G. Ploussard, *Reliability of Serial Prostate Magnetic Resonance Imaging to Detect Prostate Cancer Progression During Active Surveillance: A Systematic Review and Meta-analysis*, *European Urology*, Volume 80, Issue 5, 2021, Pages 549-563, ISSN 0302-2838, <https://doi.org/10.1016/j.eururo.2021.05.001>. (<https://www.sciencedirect.com/science/article/pii/S0302283821003250>)
- [7] Maudy C. W. Gayet, Anouk A. M. A. van der Aa, Harrie P. Beerlage, Bart Ph Schrier, Maaike Gielens, Roel Heesakkers, Gerrit J. Jager, Peter F.A. Mulders, Hessel Wijckstra, *Cancer Detection Rates of Systematic and Targeted Prostate Biopsies after Biparametric MRI*, *Prostate Cancer*, vol. 2020, Article ID 4626781, 6 pages, 2020. <https://doi.org/10.1155/2020/4626781>
- [8] Penzkofer, Tobias, and Clare M Tempny-Afdhal. *Prostate cancer detection and diagnosis: the role of MR and its comparison with other diagnostic modalities--a radiologist's perspective*. *NMR in biomedicine* vol. 27,1 (2014): 3-15. doi:10.1002/nbm.3002
- [9] Kelley, R Phelps et al. *The use of prostate MR for targeting prostate biopsies*. *BJR open* vol. 1,1 20180044. 19 Jun. 2019, doi:10.1259/bjro.20180044
- [10] European Association of Urology 2021 – *Guidelines on Prostate Cancer*
- [11] Boesen L. *Magnetic resonance imaging-transrectal ultrasound image fusion guidance of prostate biopsies: current status, challenges and future perspectives*. *Scand J Urol*. 2019 Apr-Jun;53(2-3):89-96. doi: 10.1080/21681805.2019.1600581. Epub 2019 Apr 22. PMID: 31006323.
- [12] Kongnyuy, Michael et al. *Magnetic Resonance Imaging-Ultrasound Fusion-Guided Prostate Biopsy: Review of Technology, Techniques, and Outcomes*. *Current urology reports* vol. 17,4 (2016): 32. doi:10.1007/s11934-016-0589-z
- [13] Huang GL, Kang CH, Lee WC, Chiang PH. *Comparisons of cancer detection rate and complications between transrectal and transperineal prostate biopsy approaches - a single center preliminary study*. *BMC Urol*. 2019 Oct 28;19(1):101. doi: 10.1186/s12894-019-0539-4. PMID: 31660936; PMCID: PMC6816188.
- [14] Shinohara K, Nguyen H, Masic S. *Management of an increasing prostate-specific antigen level after negative prostate biopsy*. *The Urologic clinics of North America*. 2014;41(2):327-38.
- [15] Andrew B. Rosenkrantz, MD; Sadhna Verma, MD; Peter Choyke, MD; Steven C. Eberhardt, MD; Masoom A. Haider, MD; Daniel J. Margolis, MD; Samir S. Taneja, MD; Krishnanath Gaitonde, MD; Scott E. Eggener, MD; Leonard S. Marks, MD; Peter Pinto, MD; Geoffrey A. Sonn, MD. *Prostate MRI and MRI-Targeted Biopsy in Patients with Prior Negative Biopsy*. *American Urological Association*. 2016.